



## CLINICAL RESEARCH

Vi Dao, DDS,\* Sanjay M. Mallya, BDS, MDS, PhD,<sup>†</sup> Daniela Markovic, MS,<sup>‡</sup> Sotirios Tetradis, DDS, PhD,<sup>†</sup> and Nadia Chugal, DDS, MS, MPH\*

# Prevalence and Characteristics of Root Resorption Identified in Cone-Beam Computed Tomography Scans

## SIGNIFICANCE

Root resorption is a destructive process and can remain asymptomatic. We report root resorption prevalence in 1148 consecutive CBCT examinations. The high prevalence of resorption as incidental finding underscores the importance of evaluating all imaged teeth to prevent underdiagnosis.

## ABSTRACT

**Introduction:** Root resorption is a destructive process that compromises tooth structure and can result in tooth loss. Often it remains asymptomatic and is an incidental finding on radiographic examinations. The purpose of this study was to determine prevalence and characteristics of root resorption in patients referred for cone-beam computed tomography (CBCT) imaging for a variety of indications. **Methods:** The study included CBCT scans of 1086 consecutive patients referred for CBCT imaging over an 18-month period. A total of 1148 scans were acquired. Data were abstracted from radiology reports, and prevalence estimates of resorption were computed for the aggregate sample and also across specific indications. **Results:** Resorption was identified in 171 patients (15.7%, 95% CI: 13.6%–17.9%) and in 249 teeth with a prevalence range of 2.6%–92.3% across specific indications. An 18.7% of the patients had 2 resorption sites whereas 8.8% had 3 or more resorption sites. The majority of affected teeth were anteriors (43.8%), followed by molars (40.6%) and premolars (14.5%). The most prevalent resorption types were external (29.3%), cervical (22.5%), infection-induced apical resorption (13.7%), internal (9.6%), and impacted tooth induced (8.8%). The majority of teeth with resorption did not have prior endodontic treatment (73.9%) and had radiographically normal periapex (69.5%). Of 249 teeth with resorption, 31% presented as incidental finding. The prevalence of incidental findings of resorption increased with age,  $P < .05$ , and was significantly lower for anterior teeth (20.2%) as compared to premolars (41.7%) and molars (36.6%), ( $P < .05$ ). **Conclusion:** The high proportion of incidental findings of resorption detected by CBCT suggests that resorption is not recognized/detected by conventional radiography and therefore remains underdiagnosed. (*J Endod* 2023;49:144–154.)

## KEY WORDS

Cone-beam computed tomography; incidental finding; prevalence; prognosis; root resorption

From the \*UCLA School of Dentistry, Section of Endodontics; <sup>†</sup>Section of Oral and Maxillofacial Radiology, UCLA School of Dentistry; and <sup>‡</sup>David Geffen School of Medicine, Division of General Internal Medicine and Health Sciences Research, Los Angeles, California

Address requests for reprints to Nadia Chugal, UCLA School of Dentistry, Section of Endodontics, CHS A3-078, 10833 Le Conte Ave, Los Angeles, CA 90095-1668. E-mail address: [nchugal@dentistry.ucla.edu](mailto:nchugal@dentistry.ucla.edu) 0099-2399

Copyright © 2022 The Authors. Published by Elsevier Inc. on behalf of American Association of Endodontists. This is an open access article under the CC BY license (<http://creativecommons.org/licenses/by/4.0/>). <https://doi.org/10.1016/j.joen.2022.11.006>

Root resorption is a destructive process that can result in tooth loss. The process is characterized by a loss of dentine and cementum due to either physiologic or pathologic processes<sup>1</sup>. The pathophysiology involves osteoclastic activity of the root surface affected by varied stimulation factors<sup>2–4</sup>.

The process of resorption has been studied in response to bacterial infection<sup>5–7</sup>, pressure from impacted teeth<sup>2,3,8</sup>, trauma<sup>9–12</sup>, mechanical forces due to orthodontic treatment<sup>13</sup>, and intracoronal bleaching<sup>14,15</sup>. It has been studied in vital and endodontically-treated teeth<sup>16–18</sup> and as part of a physiologic process of resorption of deciduous teeth<sup>1,19</sup>.

Root resorption is broadly classified as either internal or external based on location in relation to the root surface<sup>3</sup>. Other forms of root resorption include cervical, infection induced, replacement, or impacted-teeth induced resorption. Multiple studies have described different types of resorption, their clinical presentation, histopathology<sup>19–24</sup>, and treatment<sup>25–27</sup>.

Until recently, detection of resorption depended primarily on conventional 2-dimensional radiographs and/or clinical examination. This provided the basis for a widely used classification of resorption<sup>20</sup>. There are however detection limitations due to sensitivity/specificity of conventional radiographs and difficulties in visualization of the resorption sites due to overlapping anatomical

structures. Cone-beam computed tomography (CBCT) imaging has increased sensitivity of detection of root resorption lesions<sup>28–32</sup> and provides greater details of the location and its extent, a reflection of the 3-dimensional nature of CBCT imaging<sup>30–32</sup>. This led to a more recent, CBCT-based 3-dimensional classification of external cervical root resorption<sup>33</sup>.

With increasing use of CBCT in dentistry, it is important that dentists recognize the spectrum of manifestations of root resorption and be aware of its frequency of detection. Although many studies have explored the etiology, diagnosis and classification of root resorption, epidemiological studies are few<sup>21,34</sup>. Thus, prevalence and characteristics of root resorption remain unknown.

The purpose of this study was to determine the prevalence of root resorption and its subcategories as stated in radiology reports issued for CBCT scans of patients referred for a variety of indications, to an oral radiology department at a Dental School in the American Southwest.

## MATERIALS AND METHODS

The study sample included CBCT scans of all consecutive patients ( $n = 1086$ ) referred to University of California Los Angeles School of Dentistry for CBCT imaging between January 1, 2018 and June 30, 2019. A total of 1148 scans were acquired, using the 3D Accutomo 170 scanner (J. Morita) and NewTom 5G (Verona, Italy) CBCT scanners and included limited maxillofacial and craniofacial fields of view (FOV). The University of California Los Angeles Institutional Review Board approved this study, IRB #14-000942.

All CBCT scans included a radiology report written by 1 of 3 calibrated board certified oral and maxillofacial radiologists. All 3 radiologists are dentists with formal training in oral and maxillofacial radiology and are certified by the American Board of Oral and Maxillofacial Radiology. Radiologists in this group consistently follow the same systematic approach to comprehensive evaluation of the entire imaged CBCT volume and describe all pertinent findings irrelevant of the area of interest or purpose of the scan. As part of the routine evaluation protocol, all scans are evaluated for the presence of any dental disease, including tooth/root resorption. The reports typically identify the tooth with resorption, describe its origin (internal vs external), its location, and comment on related pertinent findings.

Data for this study were abstracted from the radiology reports and selected variables

were entered/recorded into an excel database. These reports did not contain clinical data or the results of sensibility tests. The variables evaluated included: (1) indications for ordering the CBCT scan (endodontic survey/cracked tooth survey, implant survey, TMJ survey, orthodontic treatment survey, evaluation of tooth resorption, evaluation of nonodontogenic pathosis, impacted tooth/teeth and/or general evaluation, evaluation of supernumerary tooth/teeth, jaw/tooth trauma, periodontitis, periodontal disease, and/or other indications); (2) universal tooth number and tooth group (anterior, premolar, molar); (3) demographic data (age and sex); (4) presence and type of resorption; (5) presence of periapical/periradicular pathosis; and (6) evidence of prior endodontic treatment.

The tooth/teeth identified as having a resorption were recorded and type of resorption described and categorized following the American Association of Endodontics Glossary of Endodontic Terms<sup>35</sup>. Briefly the categories of resorption are identified as below.

*Cervical root resorption* originates in the cervical region of the tooth and typically involving the coronal third of the root<sup>20</sup>. It is distinguished from external root resorption by its location and by its invasive strand-like extension into the dentin (Fig. 1A-C).

*External inflammatory root resorption* is characterized/defined as radiolucent defects along the apical and middle thirds of the root surface, with or without pulp involvement (Fig. 1D). This category includes *infection-induced resorption* (apical inflammatory resorption) induced by apical periodontitis, and may cause blunting of the root apex or widening of the apical foramen<sup>5–7,36</sup>. Teeth with apical periodontitis were categorized in this group (Fig. 1E).

*Pressure-induced resorption* is evidenced radiographically adjacent to and in the path of eruption of an impacted tooth (Fig. 1F).

*Internal resorption* is recognized as one or more localized dilations of the pulp canal and may or may not extend to the root surface to cause perforation.<sup>19,21–23</sup> (Fig. 1G).

*Replacement resorption* is considered when the resorptive defect is occupied by bone, recognized radiographically as effacement of the periodontal ligament space and lamina dura, with localized fusion of the tooth to bone (Fig. 1H).

*Root resorption of nonodontogenic origin* (Fig. 1I).

*Physiologic resorption* is defined as radiographic evidence of primary tooth root loss adjacent to a succedaneous tooth (Fig. 1J).

If a resorption was observed, but was not an indication for the referral, it was recorded as an incidental finding of resorption (IFR).

## Statistical Analysis

Categorical variables were summarized as frequency (percentage); whereas continuous variables were summarized as mean (SD).

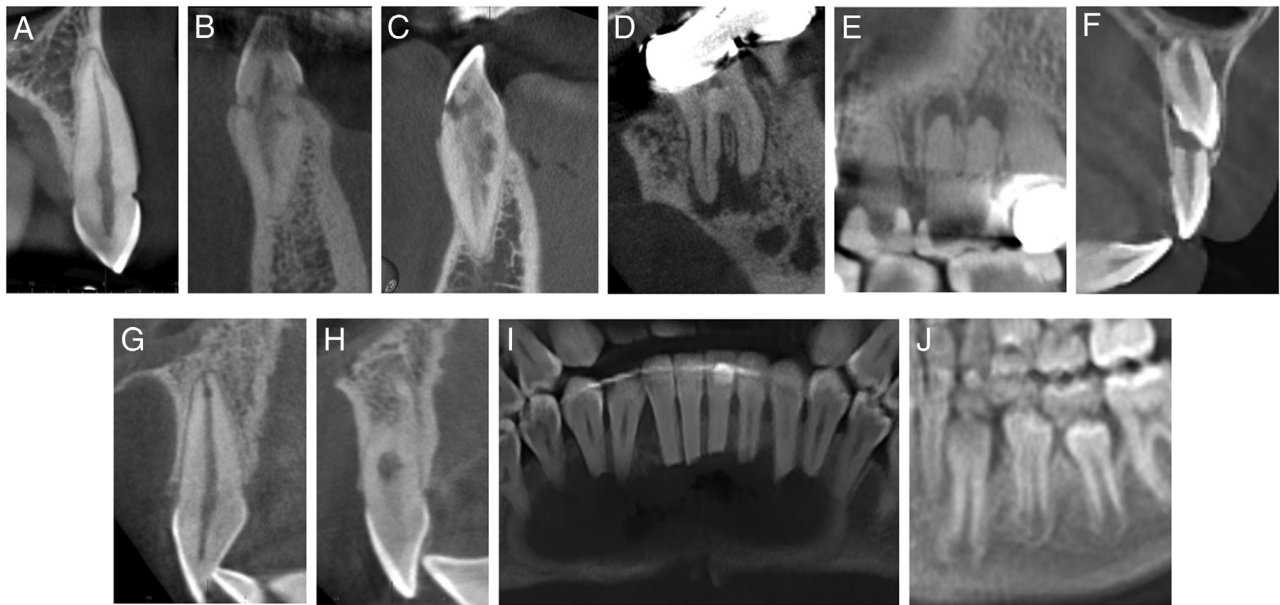
Patient level variables were compared by resorption status using the chi-square test or the Wilcoxon rank sum test for comparisons involving categorical and continuous variables, respectively. The prevalence of resorption was calculated in aggregate and after stratifying by demographic variables. We used the normal approximation to calculate the 95% confidence intervals for the above prevalence estimates. Prevalence estimates were compared across groups using the chi-square test.

Scan level variables, such as CBCT indication, were compared by resorption status using the general estimating equations logistic analysis considering that observations (scans) within the same patient were not independent.

The prevalence of resorption according to type was compared across specific variables using chi-square tests. We evaluated factors associated with the presence of incidental findings of resorption using the general estimating equations logistic model considering that observations (teeth) within the same patient were not independent. Model 1 was adjusted for age group, sex, tooth group, periapical status/diagnosis, and history of prior endodontic treatment. Model 2 was adjusted for these same variables as well as for CBCT indication categories. Final models were selected using a backwards procedure for variable selection. The numbers of resorption sites per patient were compared by demographic variables using the Wilcoxon rank sum test. All analyses were conducted using SAS version 9.4 (Copyright © 2016 by SAS Institute Inc, Cary, NC, USA). Since the above analyses were exploratory in nature, no adjustments for multiple comparisons were performed, and a nominal  $P$ -value of  $< .05$  was considered statistically significant.

## Sample Size

The purpose of the study was to obtain descriptive estimates of the per patient prevalence of resorption on CBCT imaging. An a priori sample size calculation of per patient prevalence estimates was not performed as the analysis was based on a convenience sample of all CBCT scans among consecutive patients over an 18-month study period.



**FIGURE 1** – Root resorption types: A-C. Cervical root resorption demonstrating increasing severity. D. External inflammatory root resorption. E. Apical infection-induced root resorption. F. Pressure-induced root resorption. G. Internal root resorption. H. Internal and replacement root resorption. I. Root resorption of non-odontogenic origin. J. Physiologic root resorption.

## RESULTS

### Characteristics of the Study Sample

A sample of 1148 scanned images corresponding to 1086 patients was included in the analysis. Demographic and clinical characteristics of the study sample are presented in Table 1. Mean age was 51.3 years (SD = 18.7) and 58.7% of patients were female. Mean age was 52.1 years (SD = 19.1) for male patients vs 50.8 years (SD = 18.5) for female patients. The majority of imaged areas/teeth (93.9%) were captured with 3D Accutomo 170 scanner (J Morita), whereas only 6.1% were imaged with NewTom 5G CBCT scanner.

### Prevalence of Resorption in the Aggregate Sample and by Demographics

Of the 1086 patients, 171 (15.7%, 95% CI: 13.6%–17.9%) had a resorption finding on the CBCT scan (Table 2). The prevalence of resorption was similar among males and females (17.9%, 95% CI: 14.3%–21.4% vs 14.3%, 95% CI: 11.5%–17%,  $P > .05$ ) and did not significantly vary across different age groups (range: 12%–19%,  $P > .05$ ).

### Indications for CBCT Scan by Resorption Status

The indications for CBCT scan were distributed differently between groups with and

without resorption, ( $P < .001$ ). For patient-scans without resorption, the most frequent indications were endodontic treatment (29.8%), implant placement (28.7%), TMJ evaluation (15.1%), and diagnosis of nonodontogenic pathosis (12.1%). For patient-scans with resorption, the most frequent indications were surveys for endodontic treatment (47.5%), implants (16.4%), nonodontogenic pathosis (9.6%), and impacted tooth (7.3%).

### Prevalence of Resorption by Indications for CBCT Scan

The probability/prevalence of resorption for each clinical indication is shown in Table 3.

**TABLE 1** - Description of the Study Sample

Variable	Overall (n = 1148 scans)	No resorption (n = 971 scans)	Resorption (n = 177 scans)	P value
Scan Type, n (%)				.195
Morita	1078 (93.9)	908 (93.5)	170 (96.0)	
Newtom	70 (6.1)	63 (6.5)	7 (4.0)	
	(n = 1086 patients)	(n = 915 patients)	(n = 171 patients)	
Age, years, mean (SD)	51.3 (18.7)	51.5 (18.7)	50.8 (18.8)	.658
Male, n (%)	448 (41.3)	368 (40.2)	80 (46.8)	.381
Female, n (%)	638 (58.7)	547 (59.8)	91 (53.2)	

**TABLE 2 - Prevalence of Resorption by Demographics**

Variable	Overall	No resorption	Resorption	P value
Patients, n (%)	1086 (100)	915 (84.3)	171 (15.7)	
Male, n (%)	448 (41.3)	368 (82.1)	80 (17.9)	.381
Female, n (%)	638 (58.7)	547 (85.7)	91 (14.3)	
Age Group, years, n (%)				.262
≤20	67 (6.2)	57 (85.1)	10 (14.9)	
21–30	112 (10.3)	92 (82.1)	20 (17.9)	
31–40	129 (11.9)	108 (83.7)	21 (16.3)	
41–50	159 (14.6)	128 (80.5)	31 (19.5)	
51–60	210 (19.3)	184 (87.6)	26 (12.4)	
61–70	237 (21.8)	200 (84.4)	37 (15.6)	
>70	172 (15.8)	146 (84.9)	26 (15.1)	

Among indications with the highest prevalence of resorption were “resorption present” (92.3%), referral for multiple indications (42.9%), endodontic treatment (22.5%), and impacted tooth (18.8%).

**Characteristics of Teeth with Resorption on CBCT Scans**

The clinical features of teeth with resorption findings on CBCT are summarized in Figure 2. The majority of affected teeth were incisors and canines (43.8%), representing the anterior tooth group, followed by molars (40.6%), premolars (14.5%), and lastly primary teeth (1.1%), (Fig. 2A). Most teeth with resorption did not have prior endodontic treatment (73.9%), (Fig. 2B) and had a radiographically normal periapex (69.5%), (Fig. 2C).

**Prevalence of Resorption by its Type/Category**

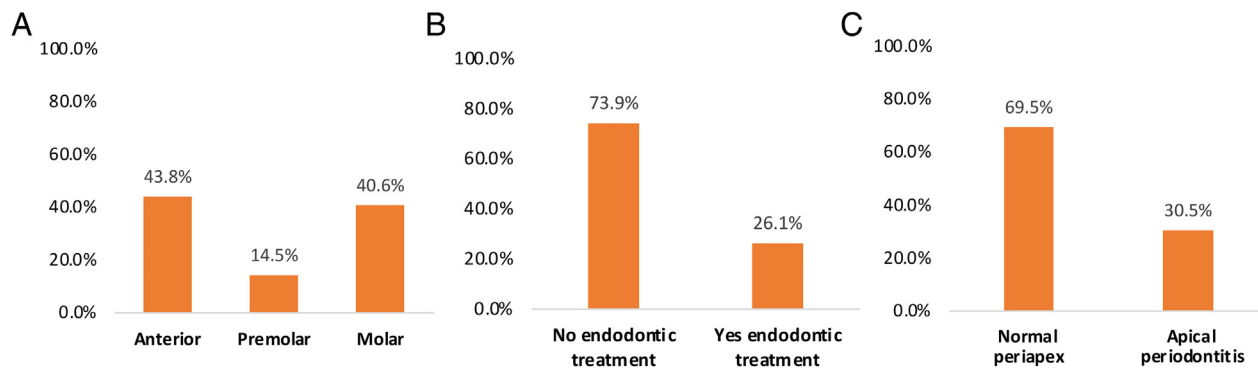
The prevalence of the resorption types for the 249 affected teeth is shown in Figure 3A. The most common types of resorption included external (29.3%), followed by cervical (22.5%), apical/infection induced (13.7%), internal (9.6%), impacted tooth induced (8.8%), and replacement resorption (4.8%). The prevalence of the 6 most common resorption types was analyzed according to clinical tooth level characteristics as summarized in Figure 3B-D. There were only 3 primary teeth representing about 1% of the sample with resorption.

The prevalence of different resorption types significantly varied across different tooth groups (overall effect:  $P < .001$ ) (Fig. 3B). The resorption types that were significantly different

across tooth groups included apical infection induced resorption, internal resorption, and impacted tooth resorption. Notably, the prevalence of apical infection induced resorption was more than 4 times greater for premolars (22.2%) or molars (20.8%) as compared to anterior teeth (4.6%) ( $P < .001$ ). Moreover, the prevalence of internal resorption was highest for anterior teeth at 15.6%, an almost 4 times greater prevalence than for molars (4.0%) and almost 2 times greater prevalence than for premolars (8.3%) ( $P < .05$ ). On the other hand, the prevalence of impacted tooth resorption was highest for molars at 14.9% compared to 0% for premolars and 6.4% for anterior teeth ( $P < .05$ ). The prevalence of external and cervical resorption types did not significantly differ across tooth groups.

**TABLE 3 - Prevalence of Resorption by Indications for CBCT Imaging**

Variable	Overall	No resorption	Resorption	P value
Scans, n (%)	1148 (100)	971 (84.6)	177 (15.4)	
Indication				<.001
Endodontic Treatment	373 (32.5)	289 (77.5)	84 (22.5)	
Implant survey	308 (26.8)	279 (90.6)	29 (9.4)	
TMJ	151 (13.2)	147 (97.4)	4 (2.6)	
NonOdontogenic Pathosis	134 (11.7)	117 (87.3)	17 (12.7)	
Impacted tooth	69 (6)	56 (81.2)	13 (18.8)	
Other	53 (4.6)	41 (77.4)	12 (22.6)	
General evaluation	23 (2)	22 (95.7)	1 (4.3)	
Orthodontic Treatment	17 (1.5)	15 (88.2)	2 (11.8)	
Multiple Indications	7 (0.6)	4 (57.1)	3 (42.9)	
Resorption Present	13 (1.1)	1 (7.7)	12 (92.3)	



**FIGURE 2** – Characteristics of teeth diagnosed with a resorption,  $n = 249$ , according to: A. Tooth group; B. Prior endodontic treatment; and C. Periapical diagnosis.

The prevalence of different resorption types also significantly varied according to prior endodontic treatment ( $P < .001$ ) (Fig. 3C). The specific resorption types that were significantly different between teeth with and without prior endodontic treatment included apical infection induced resorption, cervical resorption, internal resorption, and impacted tooth resorption. Notably, teeth with prior endodontic treatment were significantly more likely to be affected by apical infection induced resorption (43.1%) compared to teeth without prior endodontic treatment (only 3.7%) ( $P < .001$ ). Nonendodontically treated teeth were significantly more likely to be affected by either cervical resorption (26.1% vs 12.3%,  $P < .05$ ), internal resorption (12% vs 3.1%,  $P < .05$ ), or impacted tooth resorption (12% vs 0%,  $P < .01$ ). The prevalence of external resorption did not differ according to prior endodontic treatment.

Finally, the prevalence of different resorption types significantly differed according to radiographic evidence of periapical lesions ( $P < .001$ ) (Fig. 3D). The specific resorption types that significantly differed between teeth with and without periapical lesions included: periapical infection induced, cervical, internal, and impacted tooth resorption. Notably, teeth with a periapical lesion were significantly more likely to be affected by apical infection induced resorption (44.8%) compared to teeth with normal apical structures (0%) ( $P < .001$ ). As compared to teeth with periapical lesions, teeth with a radiographically normal periapex were considerably more likely to be affected by either cervical resorption (28.3% vs 9.2%,  $P < .005$ ), internal resorption (13.3% vs 1.3%,  $P < .005$ ), or impacted tooth resorption (12.7% vs 0%,  $P < .005$ ). The prevalence of external resorption did not significantly differ between these groups. We also examined whether the prevalence of different resorption

types differed according to type of indication for CBCT referral. The prevalence of cervical resorption differed significantly across different indication categories ( $P < .001$ ). Notably, cervical resorption was most prevalent for endodontic treatment (30.5%), followed by implant survey (25%) and resorption present as primary diagnosis (23.5%), vs  $<10\%$  otherwise. The prevalence of impacted tooth resorption was, not surprisingly, greatest for impacted tooth indication at 58.8% vs  $<15\%$  for any other indication categories ( $P < .005$ ).

There was no evidence that the prevalence of different resorption types varied according to sex or age group (results not shown).

### Presence of Multiple Resorption Sites

The numbers of resorption sites per patient are shown in Table 4. Of 171 patients who were diagnosed with having a resorption, 32 (18.7%) had 2 resorption sites whereas 15 (8.7%) had 3 or more resorption sites. The number of resorption sites per patient did not significantly vary according to age or sex.

### Prevalence of Incidental Findings of Resorption

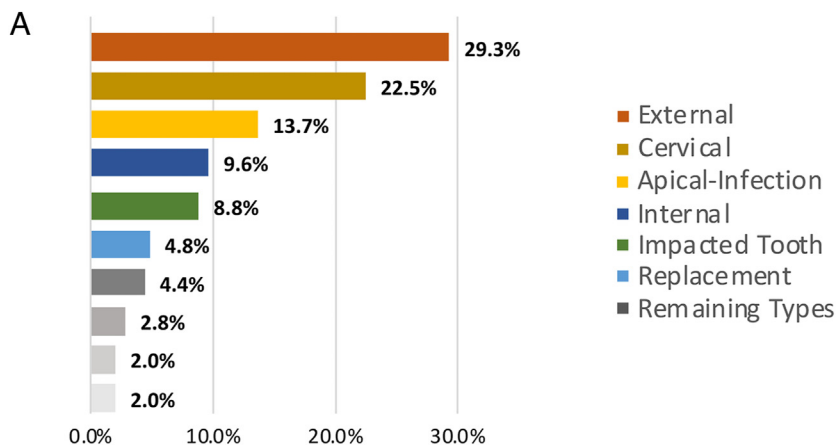
Of the 249 teeth with resorption, 77 (31%) are presented as IFR. Prevalence of IFR varied significantly among different indications for CBCT scan as presented in Table 5. The prevalence of IFR was highest for TMJ survey ( $n = 6$ , 100%), implant survey ( $n = 41$ , 93.2%), and nonodontogenic pathosis survey ( $n = 17$ , 68.0%), whereas it was among the lowest for endodontic treatment (7.6%).

In univariable analysis, we compared the prevalence of IFR according to demographic and clinical characteristics (Fig. 4). Most notably, the prevalence of IFR increased with age ranging from 7.7% for ages  $<20$  years to

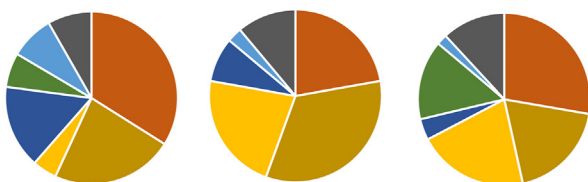
36%–42% for ages  $>50$  years,  $P < .05$  (Fig. 4A). Moreover, the prevalence of IFR was significantly smaller for anterior teeth (20.2%) as compared to premolars (41.7%) and molars (36.6%),  $P < .05$  (Fig. 4B). The prevalence of IFR did not significantly vary by previous endodontic treatment or presence of periapical pathosis. In the univariable (unadjusted) analysis the proportions with IFR tended to be higher for teeth without prior endodontic treatment but results were not statistically significant (unadjusted OR = 0.66,  $P < .05$ ).

Multivariable Model 1 identified 3 factors that were independently associated with the odds of IFR. This included age, tooth group, and (history of) prior endodontic treatment, although the last factor did not quite reach statistical significance. For example, each 10-year increase in age was associated with a 28% increase in the odds of IFR (adjusted OR = 1.28; 95% CI: 1.04–1.58;  $P < .05$ ) after controlling for the other covariates. Moreover, the increased odds of IFR was 2.9 times higher for molar teeth and 3.1 times higher for premolar teeth as compared to anterior teeth after controlling for the other covariates (premolars: adjusted OR = 2.91,  $P < .05$ ; molars: adjusted OR = 3.07,  $P < .005$ ). Finally, prior endodontic treatment tended to be associated with a 52% reduction in the odds of IFR by CBCT after controlling for the other factors, although it did not reach significance (OR = 0.48,  $P > .05$ ). In multivariable Model 2 we adjusted for the same variables as in Model 1 as well as for specific indications. Model 2 showed that the odds of IFR was significantly higher for implant survey (adjusted OR = 202.3,  $P < .001$ ) and for nonodontogenic pathosis referral (OR = 29.04,  $P < .001$ ) as compared to endodontic treatment after controlling for the other covariates. We found that age and tooth group remained significantly associated with the odds of IFR in this model. For example,





**B** Anterior, n = 109 teeth Premolar, n = 36 teeth Molar, n = 101 teeth



**C** No endodontic treatment, n = 184 teeth Yes endodontic treatment, n = 65 teeth



**D** Normal periapex, n = 173 teeth Apical periodontitis, n = 76 teeth



**FIGURE 3** – Prevalence of resorption types in the A. Overall sample of teeth with resorption, n = 249, and according to B. Tooth group 3 primary teeth were excluded from anterior tooth group analysis, thus tooth group n = 246. C. Prior endodontic treatment and D. Periapical diagnosis.

patients aged >30 years had a 6-fold increase in the odds of IFR, whereas molar and premolar teeth had close to 4 times greater odds of IFR as compared to anterior teeth.

## DISCUSSION

Root resorption is a challenging clinical condition that may complicate dental treatment. Resorption is most often silent and progressing until it causes extensive compromise of the dental structures that require major treatment interventions and often

result in tooth loss. Identification of early resorptive changes is vital to improve treatment outcomes. However, root resorption is not clinically apparent and dental practitioners depend on radiographic imaging to detect presence and assess extent of resorption. CBCT technology has provided significant advantages over 2-dimensional radiographs in assessing the dental and orofacial structures<sup>28,29</sup>. Our goal in this manuscript was to assess the prevalence of various types of root resorption in a series of consecutive CBCT scans taken in our

**TABLE 4** - Number of Resorption Sites per Patient

Number of sites per patient	Patients, n (%)
1	124 (72.5)
2	32 (18.7)
3	7 (4.4)
4	4 (2.3)
5	1 (0.6)
6	2 (1.2)
7	1 (0.6)
Total	171 (100)

University's Oral and Maxillofacial Radiology clinic for a variety of diagnostic goals. Our findings show that root resorption is not an infrequent finding, is often discovered incidentally, can affect multiple teeth in the same patient, and can be seen in CBCT scans of variable FOV taken for a variety of clinical indications.

Patients were referred for CBCT imaging for a variety of indications. We sought to determine the frequency with which root resorption is present on CBCT scans among patients presenting with referrals at our institution separately by each stated indication and in aggregate. Most cases of resorption were identified in CBCT scans with a referral indication of endodontic treatment or implant survey. The contribution of 3 primary teeth representing about 1% of the total resorption cases is minimal but may draw attention from the research community for additional investigation. The results of our study show that the overall per patient prevalence of root resorption on CBCT scans was 15.7%.

Resorptive changes were not distributed uniformly. Most of the affected teeth were anterior teeth, followed by molars, and lastly premolars. The reasons for this occurrence may be multiple, hypothetically, including higher risk for traumatic injuries in anterior dentition and orthodontic tooth movement to correct incisor flare and overjet<sup>10,11,14</sup>. In the majority of cases, teeth with resorption did not have prior endodontic treatment and presented with radiographically normal periapical tissues. Although no clinical data on patient symptomatology were available, these findings would suggest that the majority of teeth with resorption were vital.

We identified the distribution and frequencies of resorption types on CBCT scans. External resorption and cervical resorption account for nearly half of all resorption types. Although dental trauma is most frequently identified as a risk factor associated with resorption, only 4.8% of teeth

**TABLE 5** - Incidental Findings of Resorption (IFR) by CBCT Indication Type for 249 Teeth Diagnosed With a Resorption

Indication	Total number of teeth	Teeth with incidental findings, <i>n</i> (%)
Implant Survey	44	41 (93.2)
Nonodontogenic Pathosis	25	17 (68.0)
Endodontic treatment	118	9 (7.6)
TMJ	6	6 (100)
Other	17	3 (17.6)
General Evaluation	1	1 (100)
Orthodontic Treatment	4	0
Impacted Tooth	17	0
Resorption Present	17	0
Total	249	77 (100)

with resorption were characterized as replacement resorption<sup>2,9,11</sup>.

The apical infection induced resorption type was 4 times more prevalent among premolars and molars as compared to anterior teeth, whereas the presence of internal resorption was highest in anterior teeth. The presence of impacted tooth resorption was most highly associated with molars<sup>2,3,37</sup>.

Teeth without prior endodontic treatment had significantly higher frequencies of cervical and internal resorption compared to teeth with prior endodontic treatment. Differences in frequency and pattern of root resorption in vital and endodontically treated teeth have been described in prior studies.<sup>16–18,38</sup> The reason for CBCT referral of nonendodontically treated teeth may have been evaluation of internal tooth morphology, presence of calcified canals, resorption, history of trauma, etc.<sup>39</sup> However, teeth with prior endodontic treatment had a much higher frequency of infection-induced apical resorption compared to teeth without. The reason for CBCT referral was likely the evaluation for possible causes of persistent or recurrent apical periodontitis or patient symptomatology to explore unsuccessful endodontic treatment outcome<sup>39</sup>. Replacement resorption had a similar distribution in teeth without and with prior endodontic treatment.

Cervical, internal and impacted tooth associated resorption were higher in teeth with normal periapex compared to teeth with apical periodontitis. Apical infection induced resorption was present only in teeth with apical periodontitis and none in teeth with normal periapex.

Nearly a quarter of patients diagnosed with resorption, had more than 1 tooth affected by the resorption and close to 10% showed 3 or more resorption sites. The number of resorption sites per patient on CBCT scans did not vary significantly according to age or sex, underscoring the need to critically evaluate teeth for presence of resorption, in all patients imaged by CBCT scanning, regardless of their age or gender. Furthermore, this finding has important implications for patient management. If a resorption is identified in 1 tooth, it is recommended to carefully inspect adjacent teeth and all areas of the oral cavity that have been included in the scan for signs of tooth resorption. Clinicians should make a conscious effort to meticulously explore the presence of resorption in the whole dentition, even if it is not in the area of primary concern or a reason for referral. For example, a medium FOV scan to assess an edentulous implant site in the lower right mandible might reveal root resorption in teeth of the upper left maxilla. Potentially, this study may have underestimated the prevalence of multitooth resorption as most scans were limited field of view CBCT, where only a small segment of the dentoalveolar arch is imaged. Nevertheless, more than 25% of the patients with resorption had more than 1 affected tooth, emphasizing that multitooth involvement is a frequent finding among patients presenting for referrals at this institution.

Because detailed clinical and radiographic history was not available, in our study we relied on the indication provided by the clinicians for obtaining the CBCT scan. Thus, if the referring dentists did not specifically

identify the presence of resorption in the imaging referral notes, the presence of resorption was considered incidental. Following this workflow, an unanticipated finding of our study was that resorption was an incidental finding in nearly a third of the teeth with resorption. A likely explanation for this high prevalence of IFR is the fact that teeth with resorption often remain asymptomatic. A variable that undoubtedly contributed to the failure to diagnose resorption based on clinical findings and intraoral radiography is the experience of the referring dentists. Although we did not have specific details of the experience of the referrals, it is reasonable to assume that in an academic setting, trainees might not have reached the peak of their diagnostic acumen. Notwithstanding the reasons underlying the high IFR, a thorough, detailed assessment of all the teeth imaged by the CBCT scan is essential irrelevant of patient symptoms, referring dentists area of interest or treatment planning goals.

The current study identified 3 factors that were independently associated with IFR among 1148 CBCT scans, which included age, tooth group, and prior endodontic treatment. Our data shows that frequency of IFR increases with age and can go unnoticed especially among individuals above 50 years of age. The IFR frequency among CBCT scans peaked at age 50–70 years with IFR at 42% compared to IFR of 7%–25% among younger individuals. Since IFR may increase with age, a methodical evaluation for root resorption sites becomes particularly important in older patients. Differential diagnosis of resorption from root caries is a clinical conundrum, especially in older

**TABLE 6 -** Multivariable GEE Logistic Model for Predictors of Incidental Findings of Resorption (IFR)

<b>Model 1:</b>				
<b>Variable</b>	<b>OR</b>	<b>Lower 95% CL</b>	<b>Upper 95% CL</b>	<b>P value</b>
Age	1.28	1.04	1.58	.018
Tooth Group				
Premolar	2.91	1.15	7.39	.024
Molar	3.07	1.45	6.48	.003
Anterior	1.00			
Endodontic Treatment				
Yes	0.48	0.23	1.01	.052
No	1.00			

<b>Model 2:</b>				
<b>Variable</b>	<b>Odds ratio</b>	<b>Lower 95% CL</b>	<b>Upper 95% CL</b>	<b>P value</b>
Age				
>30 y	6.10	1.27	29.25	.024
≤30 y	1.00	1.00	1.00	.
Tooth Group				
Premolar	3.63	1.10	11.98	.035
Molar	4.08	1.35	12.31	.013
Anterior	1.00			
Endodontic Treatment				
Yes	0.45	0.16	1.33	.149
No	1.00			
Indication Type				
Implant Survey	202.29	32.51	1258.71	.000
Nonodontogenic Pathosis	29.04	8.14	103.67	.000
Other	4.16	1.03	16.71	.045
Endodontic Treatment	1.00			

For age, the OR corresponds to a 10-year increase.

patients<sup>40</sup>. The pattern of resorptive changes can help differentiate root caries from external cervical root resorption. For example, with external root resorption, the root is within the alveolar bone envelope, whereas with root caries there is bone exposure of the root. In addition, the pattern of radiographic resorptive changes is distinct in invasive cervical resorption vs root caries.

Another notable finding was that, the frequency of IFR was significantly the lowest for anterior teeth. The complex organization of multiple roots in posterior teeth further complicated with structure overlap and magnification, likely contributed to this finding. We would expect that resorptive changes would be easier to identify in anterior single-root vs posterior multiroot teeth. Hence, a deliberate and systematic effort should be made to carefully assess posterior teeth for resorption, especially in the older age group.

Interestingly, teeth associated with IFR were less likely to have had prior endodontic treatment. A possible explanation is that teeth with prior endodontic treatment have routine follow-up examinations to assess healing. As a result, close inspection by the treating provider may contribute to the increased detection of untoward events, thus reducing the rate of incidental findings. Furthermore, removal of the pulpal tissue eliminates the possibility of internal resorption occurrence.

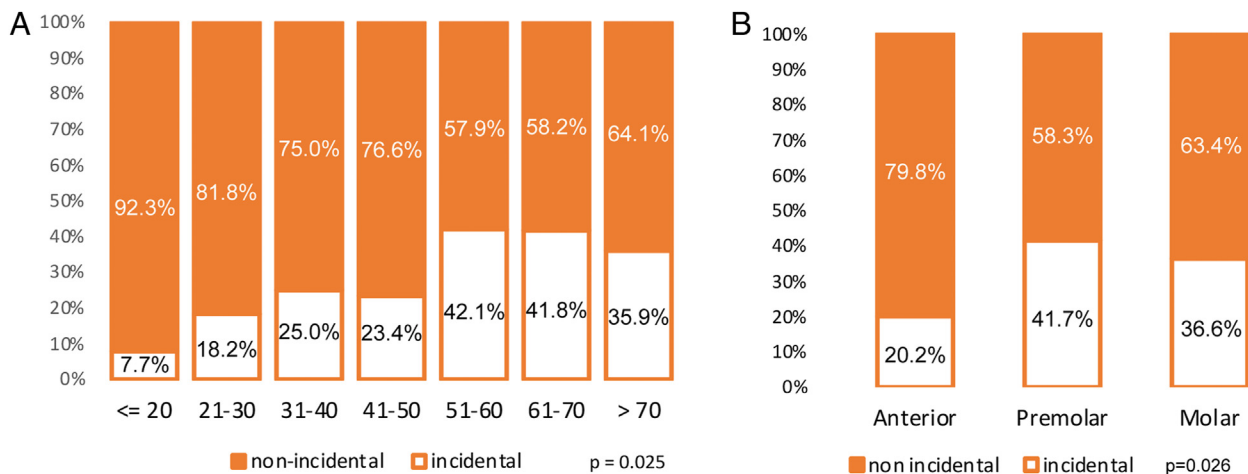
Since our study was comprised from radiographic reports on all CBCT scans obtained over a certain period of time, multiple FOV scans were included. These scans have an inherently variable spatial resolution. Assessment of resorptive changes, particularly at early phases of the disease can be difficult to detect in medium and large FOV scans. Nevertheless, our findings strongly point to the importance of an astute and meticulous

investigation of all imaged dental structures for detection of resorption.

There are limitations of our study. First, our findings are based on the analysis of CBCT scans alone. We extracted data from accurate, systematic, and thorough reports generated by formally trained and board-certified oral radiologists. No clinical data were available or collected. Therefore, the history of known risk factors for resorption, such as dental trauma and orthodontic treatment, was not available and, consequently, could not be evaluated. Future research will address these factors and their relationships.

Additionally, the scans for this study were multiple fields of view. Thus, no prevalence data of resorption in the whole dentition can be derived, since many of the scans only captured part of the dentition. Furthermore, the reported prevalence of root resorption, per patient, might be





**FIGURE 4** – Prevalence of incidental findings of resorption (IFR) in 249 teeth, by *A.* age group and *B.* tooth group. Note: These percentages were computed using tooth as unit of analysis.

underestimated, since resorption could have been present in teeth not captured in the scan. Finally, the majority of CBCT referrals originated from within the institution, and some nearby private practices in Los Angeles county or adjacent geographic locales. Since this is a convenience sample of CBCT scans drawn at a single center, the estimate may not generalize well to other clinical settings or those at different geographic locales.

Further multi-institutional studies using well matched control groups are needed to identify etiologic factors associated with root resorption. In light of the current study

demonstrating that resorption was a relatively frequent finding on CBCT scans, further work will be required to understand this condition more fully. That knowledge can further aid in the development of more efficient screening, accurate diagnosis, and appropriate treatment at earlier stages of root destruction as to improve treatment outcomes and prevent tooth loss.

### CONCLUSION

This study demonstrated high rate of root resorption and in particular, a high rate of

incidental finding of resorption. The IFR is more prevalent in posterior teeth of older individuals and may mimic root caries. Therefore, systematic evaluation, early diagnosis, and astute intervention are recommended for optimal prognosis of the affected teeth to gain improved treatment outcomes.

### ACKNOWLEDGMENTS

*Supported in part by Research and Education Fund for Excellence.*

*The authors deny any conflicts of interest related to this study.*

### REFERENCES

1. Hammarstrom L, Lindskog S. General morphological aspects of resorption of teeth and alveolar bone. *Int Endod J* 1985;18:93–108.
2. Tronstad L. Root resorption—etiology, terminology and clinical manifestations. *Endod Dent Traumatol* 1988;4:241–52.
3. Fuss Z, Tsesis I, Lin S. Root resorption - diagnosis, classification and treatment choices based on stimulation factors. *Dent Traumatol* 2003;19:175–82.
4. Iglesias-Linares A, Hartsfield JK Jr. Cellular and Molecular Pathways Leading to External Root Resorption. *J Dent Res* 2017;96:145–52.
5. Delzangles B. Apical periodontitis and resorption of the root canal wall. *Endod Dent Traumatol* 1988;4:273–7.
6. Vier FV, Figueiredo JA. Prevalence of different periapical lesions associated with human teeth and their correlation with the presence and extension of apical external root resorption. *Int Endod J* 2002;35:710–9.
7. Estrela C, Guedes OA, Rabelo LE, et al. Detection of apical inflammatory root resorption associated with periapical lesion using different methods. *Braz Dent J* 2014;25:404–8.
8. Ericson S, Kuroi PJ. Resorption of incisors after ectopic eruption of maxillary canines: a CT study. *Angle Orthod* 2000;70:415–23.

9. Andreasen JO. External root resorption: its implication in dental traumatology, paedodontics, periodontics, orthodontics and endodontics. *Int Endod J* 1985;18:109–18.
10. Heithersay GS. Invasive cervical resorption following trauma. *Aust Endod J* 1999;25:79–85.
11. Trope M. Root resorption due to dental trauma. *Endod Top* 2002;1:79–100.
12. Galler KM, Grätz EM, Widbiller M, et al. Pathophysiological mechanisms of root resorption after dental trauma: a systematic scoping review. *BMC Oral Health* 2021;21:163.
13. Weltman B, Vig KW, Fields HW, et al. Root resorption associated with orthodontic tooth movement: a systematic review. *Am J Orthod Dentofacial Orthop* 2010;137:462–76. discussion 12A.
14. Heithersay GS. Invasive cervical resorption: an analysis of potential predisposing factors. *Quintessence Int* 1999;30:83–95.
15. Friedman S, Rotstein I, Libfeld H, et al. Incidence of external root resorption and esthetic results in 58 bleached pulpless teeth. *Endod Dent Traumatol* 1988;4:23–6.
16. Spurrier SW, Hall SH, Joondeph DR, et al. A comparison of apical root resorption during orthodontic treatment in endodontically treated and vital teeth. *Am J Orthod Dentofac Orthod* 1990;97:130–4.
17. Mavridou AM, Hauben E, Wevers M, et al. Understanding external cervical resorption in vital teeth. *J Endod* 2016;42:1737–51.
18. Mavridou AM, Hauben E, Wevers M, et al. Understanding external cervical resorption patterns in endodontically treated teeth. *Int Endod J* 2017;50:1116–33.
19. Haapasalo M, Endal U. Internal inflammatory root resorption: the unknown resorption of the tooth. *Endod Top* 2006;14:60–79.
20. Heithersay GS. Clinical, radiologic, and histopathologic features of invasive cervical resorption. *Quintessence Int* 1999;30:27–37.
21. Gabor C, Tam E, Shen Y, Haapasalo M. Prevalence of internal inflammatory root resorption. *J Endod* 2012;38:24–7.
22. Patel S, Kanagasingam S, Pitt Ford T. External cervical resorption: a review. *J Endod* 2009;35:616–25.
23. Patel S, Ricucci D, Durak C, Tay F. Internal root resorption: a review. *J Endod* 2010;36:1107–21.
24. Patel S, Mavridou AM, Lambrechts P, Saberi N. External cervical resorption-part 1: histopathology, distribution and presentation. *Int Endod J* 2018;51:205–23.
25. Heithersay GS. Treatment of invasive cervical resorption: an analysis of results using topical application of trichloroacetic acid, curettage, and restoration. *Quintessence Int* 1999;30:96–110.
26. Heithersay GS. Management of tooth resorption. *Aust Dent J* 2007;52(Suppl):S105–21.
27. Patel S, Foschi F, Condon R, et al. External cervical resorption: part 2 - management. *Int Endod J* 2018;51:1224–38.
28. Patel S. New dimensions in endodontic imaging: Part 2. Cone beam computed tomography. *Int Endod J* 2009;42:463–75.
29. Patel S, Dawood A, Wilson R, et al. The detection and management of root resorption lesions using intraoral radiography and cone beam computed tomography - an *in vivo* investigation. *Int Endod J* 2009;42:831–8.
30. Durack C, Patel S, Davies J, et al. Diagnostic accuracy of small volume cone beam computed tomography and intraoral radiography for the detection of simulated external inflammatory root resorption. *Int Endod J* 2011;44:136–47.
31. Creanga A, Geha H, Sankar V, et al. Accuracy of digital periapical radiography and cone-beam computed tomography in detecting root resorption. *Imaging Sci Dent* 2015;45:153–8.
32. Patel K, Mannocci F, Patel S. The assessment and management of external cervical resorption with periapical radiographs and cone-beam computed tomography: a clinical study. *J Endod* 2016;42:1435–40.
33. Patel S, Foschi F, Mannocci F, Patel K. External cervical resorption: a three-dimensional classification. *Int Endod J* 2018;51:206–14.
34. Irinakis E, Aleksejuniene J, Shen Y, Haapasalo M. External cervical resorption: a retrospective case-control study. *J Endod* 2020;46:1420–7.
35. American Association of Endodontists. Glossary of Endodontic Terms. Tenth Edition. Available at: <https://www.aae.org/specialty/clinical-resources/glossary-endodontic-terms/>; 2020.

36. Brynolf I. Histological and roentgenological study of periapical region of human upper incisors. *Odontol Revy* 1967;18(suppl 11).
37. Oenning AC, Neves FS, Alencar PN, et al. External root resorption of the second molar associated with third molar impaction: comparison of panoramic radiography and cone beam computed tomography. *J Oral Maxillofac Surg* 2014;72:1444–55.
38. Khan AR, Fida M, Shaikh A. Evaluation of apical root resorption in endodontically treated and vital teeth in adult orthodontic subjects. *J Ayub Med Coll Abbottabad* 2018;30:506–10.
39. American Association of Endodontists. AAE and AAOMR Joint Position Statement. Use of Cone Beam Computed Tomography in Endodontics - 2015/16 Update. Available at: <https://f3f142zs0k2w1kg84k5p9i1o-wpengine.netdna-ssl.com/specialty/wp-content/uploads/sites/2/2017/06/conebeamstatement.pdf>.
40. European Society of Endodontology (ESE) Developed by, Patel S, Lambrechts P, Shemesh H, Mavridou A. European Society of Endodontology Position Statement: External Cervical Resorption. *Int Endod J* 2018;51:1323–6.